

# Case Report of Floating-Harbor Syndrome With Bilateral Cleft Lip

Jaemin Ko, DDS, MS<sup>1</sup>, Jason H. Pomerantz, MD<sup>1,2</sup>, Hazel Perry, MS, CGC<sup>1</sup>, Joseph T. Shieh, MD, PhD<sup>3</sup>, Anne M. Slavotinek, MD, PhD<sup>3</sup>, Snehlata Oberoi, BDS, DDS, MDS<sup>1</sup>, and Ophir D. Klein, MD, PhD<sup>1,3</sup>

The Cleft Palate-Craniofacial Journal  
1-5

© 2019, American Cleft Palate-Craniofacial Association  
Article reuse guidelines:  
sagepub.com/journals-permissions  
DOI: 10.1177/1055665619858257  
journals.sagepub.com/home/cpc



## Abstract

Floating-Harbor syndrome (FHS) is a rare genetic disorder caused by heterozygous mutations in the Snf2-related CREBBP activator protein (*SRCAP*) gene. The syndrome is characterized by proportional short stature, delayed bone maturation, delayed speech development, and facial dysmorphism. Submucous cleft palate and cleft lip have been reported in FHS, but to our knowledge orofacial clefting in this condition has not been assessed in detail. Here, we report on a case of bilateral cleft lip in a patient with FHS confirmed by exome sequencing.

## Keywords

genes, genetics, chromosome, Floating-Harbor syndrome, *SRCAP*, cephalometry, dental anomalies

## Introduction

Floating-Harbor syndrome (FHS; OMIM#136140) is a rare genetic disorder caused by heterozygous mutations in the Snf2-related CREBBP activator protein (*SRCAP*) gene (Hood et al., 2012). The condition was first reported in 1973 (Pelletier, 1973), and approximately 60 cases have been reported to date. The syndrome is characterized by proportional short stature, delayed bone maturation that normalizes in early or late childhood, delayed speech development, and facial characteristics (Robinson et al., 1988; White et al., 2010; Nikkel et al., 2013). The face is triangular with deep-set eyes, long eyelashes, bulbous nose, wide columella, short philtrum, and thin lips (Feingold, 2006; Hood et al., 2012).

The diagnosis of FHS is suspected when individuals show typical clinical findings and can be confirmed by sequencing of *SRCAP* (Hood et al., 2012). *SRCAP* mutations were found to be located mostly within a small region between codons 2407 and 2677 of exon 34, but also in exon 33 (Kehrer et al., 2014; Seifert et al., 2014). *SRCAP* encodes an ATPase that functions as the core catalytic component of a multiprotein chromatin-remodeling complex, and it has an important role in regulating cell growth and division (Johnston et al., 1999; Monroy et al., 2003; Messina et al., 2016).

Reports of dental anomalies in FHS are sparse, but malocclusion, hypoplastic jaw, high-arched palate, increased spacing, agenesis of mandibular incisors, supernumerary

teeth, and oligodontia have been described in association with this syndrome (Robinson et al., 1988; Houlston et al., 1994; Ala-Mello and Peippo, 2004; De Benedetto et al., 2004; Hood et al., 2012; Singh et al., 2017). Although submucous cleft palate and cleft lip have been rarely reported (Patton et al., 1991; Hood et al., 2012; Undiagnosed Diseases Network, 2019), to our knowledge orofacial clefting in this condition has not been assessed in detail. Here, we report a case of bilateral cleft lip in FHS confirmed by exome sequencing, and we describe the general features and dental findings in this patient.

<sup>1</sup> Program in Craniofacial Biology and Division of Craniofacial Anomalies, Department of Orofacial Sciences, University of California, San Francisco, CA, USA

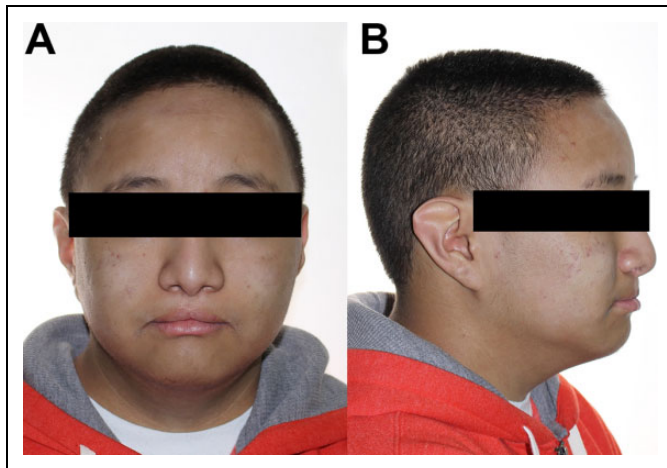
<sup>2</sup> Division of Plastic and Reconstructive Surgery, Department of Surgery, University of California San Francisco, San Francisco, CA, USA

<sup>3</sup> Division of Medical Genetics, Department of Pediatrics, and Institute for Human Genetics, University of California San Francisco, San Francisco, CA, USA

## Corresponding Author:

Ophir D. Klein, Program in Craniofacial Biology and Departments of Orofacial Sciences and Pediatrics, University of California, San Francisco, CA 94143, USA.

Email: ophir.klein@ucsf.edu



**Figure 1.** Frontal (A) and lateral (B) photographs at age 15 showing dysmorphic facial features: upslanting palpebral fissures, a simple and enlarged right ear helix, status post repair, and downturned corners of the mouth.

## Case Report

The patient presented to our institution as a 14-year-old boy who moved to the United States from Mongolia. The patient's mother reported a normal pregnancy and delivery. He was born at term with a bilateral cleft lip at a birth weight of 3.3 kg, and he had difficulty feeding due to the cleft lip. Lip repair was performed in Mongolia at age 6.

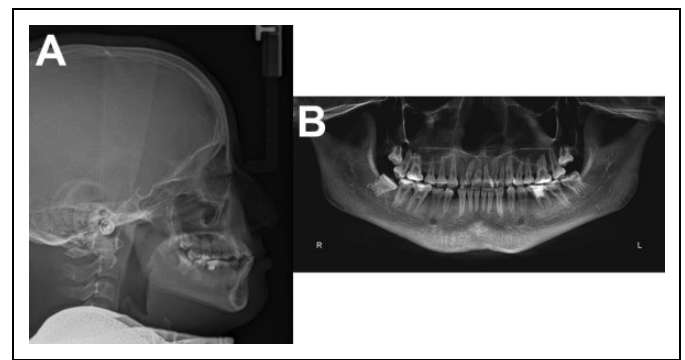
Upon arrival to our institution, significant findings included short stature, brachydactyly of all fingers, maxillary deficiency, and facial features that included upslanting palpebral fissures, a simple and enlarged right ear helix, status post repair, and downturned corners of the mouth (Figure 1). The patient's height at 148.3 cm placed him below the 1st percentile based on Centers for Disease Control and Prevention growth charts, and his bone age was just under the upper limit of 2 standard deviations.

The patient had a history of significant developmental delays. He started to walk when he was 4 years old, did not speak until the age of 5, and began to speak 2 word sentences after the age of 8. When he was 11 years old, he could speak in simple sentences and dress and feed himself, but he could not read or write. After arriving to the United States, the patient was placed in a special education program in his school and had an Individualized Education Plan in place. At the time of the initial visit to our institution, the patient was able to speak full sentences and write in his native language, but he could only make simple sentence structures and had some difficulty following complex conversations.

The family history was negative for clefts, lips pits, or mounds, and parents were nonconsanguineous. A single nucleotide polymorphism (SNP) array was performed, and an interstitial duplication within 2p15 was identified. However, as the clinical significance of this finding was unclear, the patient's and his mother's blood were collected and sent for

**Table 1.** Frequency of Clinical Characteristics in Previous Studies (Hood et al., 2012; Le Goff et al., 2013; Nikkel, et al., 2013; Seifert, et al., 2014) and Comparison With Our Patient.

Characteristics	Previous Studies	This Study
Facial dysmorphism	63/63	+
Speech delay	63/63	+
Skeletal anomalies	11/11	+
Delayed bone age	33/35	?
Short stature	50/63	+
Intellectual disability	44/54	+
Eye anomalies	15/54	–
Ear anomalies	17/63	+
Gastrointestinal malformations	5/35	–
Cardiac malformations	6/63	+/-

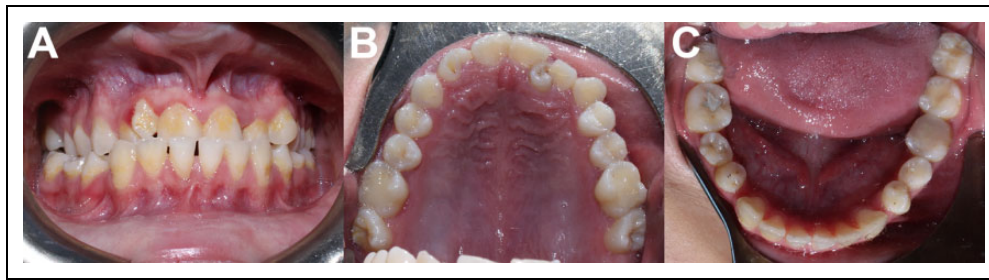

**Figure 2.** Cephalometric lateral X-ray (A) and panoramic X-ray (B) at age 15 showing flat cranial base and maxillary retrusion. Panoramic X-ray shows supernumerary teeth and abnormal roots.

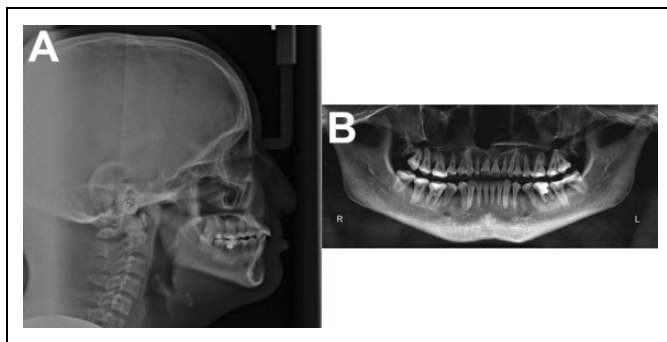
exome sequencing. This testing revealed a presumed de novo heterozygous mutation in exon 34 of *SRCAP*, which is indicative of FHS.

The patient was evaluated by Genetics, Cardiology, Endocrinology, Neurology, and the Craniofacial Center at our institution. Cardiology examination showed sinus rhythm, first-degree atrioventricular block, normal intracardiac structure, slight dilation of the aortic root, and a tiny patent foramen ovale. Endocrinology evaluation for short stature and mature bone age, including thyroid function tests, revealed no significant findings. A brain MRI was normal. Clinical characteristics in individuals with FHS in comparison with our patient are summarized in Table 1.

On examination at our Craniofacial Center, the patient presented with a slightly concave facial profile and a class III molar relationship with  $-2$  mm overjet. No centric occlusion–centric relationship shift was noted. A cephalometric radiograph revealed proclined maxillary and mandibular incisors and a skeletal class III relationship with sella-nasion-A point angle (SNA) at  $72.9^\circ$  and sella-nasion-B point angle (SNB) at  $73.1^\circ$  (Figure 2A). He had a flat cranial base angle (sella-nasion-basion) which was  $164.4^\circ$ . A panoramic X-ray revealed presence of all permanent teeth, including developing third molars. Two supernumerary teeth were also detected between the maxillary central and lateral incisors on both sides.



**Figure 3.** Frontal (A), upper (B), and lower (C) intraoral photographs at age 15 showing dental anomalies: anterior crossbite, 2 supernumerary teeth, and abnormal teeth shape.



**Figure 4.** Cephalometric lateral X-ray (A) and panoramic X-ray (B) after orthodontic treatment at age 17.

Further examination of the panoramic X-ray showed blunted and shortened roots. The patient's maxillary and mandibular second molars did not show bifurcation of roots, and the roots of the maxillary central incisors appeared to be severely dilacerated (Figure 2B). Intraorally, the patient had a posterior and anterior crossbite with an overbite of 2 mm and overjet of  $-2$  mm (Figure 3A). He had mild crowding in the maxillary anterior region and generalized spacing in the mandibular anterior region. Morphologically, the patient's mandibular second premolars were shaped more like primary molars. The patient also had multiple caries (Figure 3B and C).

Plastic surgery repaired the Stahl's ear by performing an otoplasty. A lip revision surgery was also recommended following orthodontic treatment, as a central notch/whistle was detected. Before beginning orthodontic treatment, the patient's poor oral hygiene was addressed, and prophylaxis was performed. Six composite restorations and 3 sealants were completed, and 2 supernumerary teeth were extracted. A fan-shaped palatal expander was placed for palatal expansion before comprehensive orthodontic treatment. After 2 years of orthodontic treatment, the treatment was discontinued due to poor patient compliance and poor oral hygiene, and the patient was placed in retention (Figure 4A and B).

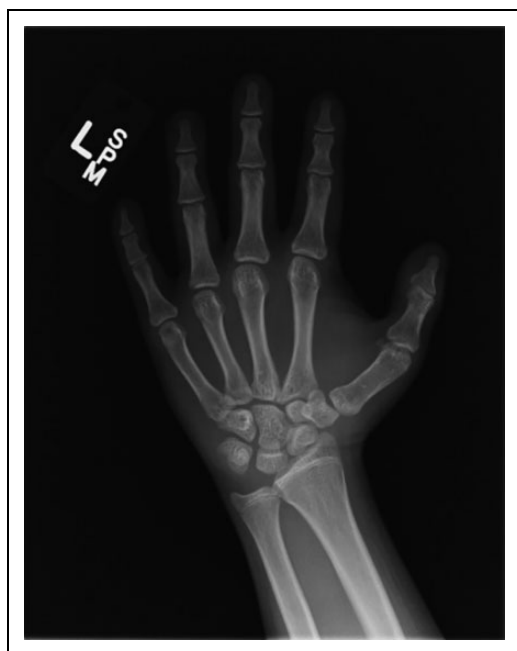Although the importance of maintaining good oral hygiene was emphasized, braces had to be removed earlier than expected because oral hygiene remained poor. After the completion of orthodontic treatment, the patient was followed up by periodontics for scaling and root planing due to generalized, severe, chronic periodontitis.

## Discussion

Here, we report a patient with FHS who had bilateral cleft lip without cleft palate. Only 2 cases of clefting in FHS have previously been reported. One report mentioned that the patient seemed to have submucous cleft palate, although this was not observed intraorally (Patton et al., 1991). Another patient with a unilateral cleft lip was also reported (Hood et al., 2012), and our patient is the first case reported with a bilateral cleft lip, to the best of our knowledge.

Floating-Harbor syndrome is caused by mutations in *SRCAP*, which encodes an ATPase that is the core catalytic component of the SRCAP complex. This ATPase functions as a transcriptional activator in CREB-mediated transcription and interacts with partners of CREB-binding protein, encoded by *CREBBP* (Johnston et al., 1999; Messina et al., 2016). Interestingly, Rubinstein-Taybi syndrome (RTS) is caused by mutations in *CREBBP*, and clinical findings of FHS and RTS are similar (Eser et al., 2017; Milani et al., 2018). For example, patients with these syndromes both typically show short stature, delayed bone age, and developmental delay. Of note, some patients with RTS have cleft lip and/or palate (Tuysuz et al., 2012). *CREBBP* is a transcriptional factor that has been reported to play essential roles in embryonic development. Therefore, it is possible that mutations in *SRCAP* that impair function of *CREBBP* are the cause of clefting in FHS. Future studies will be required to determine why clefting only affects a fraction of patients with RTS and FHS, and what other factors either protect against or predispose to clefting.

In the patient with FHS described here, both SNA and SNB were below the average values, which are  $82^\circ$  for SNA and  $80^\circ$  for SNB. The cranial base angle was  $164.4^\circ$  in this patient. The normal value of the cranial base angle is  $131^\circ$ . We believe that the SNA and SNB angles were retrognathic due to the flattening of the cranial base angle. The cranial base is an important structure for craniofacial growth and development, as the anterior cranial base influences facial growth (Enlow and Moyers, 1971; Nie, 2005). Although many individual variations of growth patterns and shapes in the cranial base do not follow the average pattern (Grayson et al., 1985), increased or decreased cranial base angles have been seen in a number of developmental disorders. Acute cranial base angles are often seen in mandibulofacial dysostosis and cleidocranial dysostosis (Kreiborg et al., 1981). Patients with Down syndrome or Turner



**Figure 5.** Hand-wrist X-ray at age 15 showing slightly advanced bone age.

syndrome have a short retrognathic face due to reduced cranial base length and increased angulation (Andersen et al., 2000; Quintanilla et al., 2002). As ours is the first report to assess cephalometric findings in FHS, it is not certain whether a flat cranial base is a typical skeletal finding in the syndrome. Our patient also had maxillary deficiency and an anterior crossbite, which might have been caused by the repaired cleft lip, because scarring can hinder normal maxillary growth. It was reported that both patients who had only lip closure surgery and patients who had lip and palatal closure surgery had similar degree of maxillary deficiency (Capelozza Filho et al., 1996). Maxillary deficiency may also be attributable to FHS. However, it is not certain if the maxillary deficiency was due to repaired cleft lip, FHS, or a combination. Surgery was not required to correct his jaw size relationship, as his A point-basion-B point (ANB) angle was  $-0.2$ .

One of the typical features of FHS is delayed bone maturation. In previous cases, most patients had delayed bone age when measured before the age of 6 years (Houlston et al., 1994; Lacombe et al., 1995; Wiltshire et al., 2005), but some reports stated that delayed bone age was still seen in patients aged between 6 and 12 years (Lacombe et al., 1995; De Benedetto et al., 2004). After the period of delay, the bone age was found to be markedly accelerated and reach normal level (Nagasaki et al., 2014). Because our patient presented to us at age 14, we were unable to determine whether he had earlier delayed bone maturation. Furthermore, when he first presented to us, his hand/wrist X-ray showed that he had an advanced bone age close to 17 years according to the standards of Greulich and Pyle.

Despite the patient's advanced bone age using a digital hand atlas (Figure 5), we found that his lateral cephalometric X-ray

at age 15 showed a cervical vertebral maturation index (CVMI) of stage 4, and at the age of 17, the CVMI was stage 5. The CVMI stages at both ages were behind his chronological ages, indicating that skeletal maturity measured by hand wrist imaging and cervical vertebral imaging were discordant. Various skeletal anomalies were observed in previous cases of FHS; most commonly, these were brachydactyly, fifth finger clinodactyly, coning and sclerosis of several epiphyses, and short phalanges (White et al., 2010; Nikkel et al., 2013). Anomalies of the spine have also been reported, including mild irregularities of the vertebral bodies, hypoplasia of the odontoid process, and abnormal curvature of the spine (Saul and Wilson, 1990; Stagi et al., 2007; Hood et al., 2012). This may suggest that assessing bone maturity with the vertebral shapes must be done with caution in FHS.

In summary, we report a patient with bilateral cleft lip in FHS. In addition to various characteristics including short stature, skeletal anomalies, and facial dysmorphism, screening for orofacial clefting should also be performed when there is a diagnosis of FHS.


#### Declaration of Conflicting Interests

The authors declare no potential conflicts of interest with respect to the research, authorship, and/or publication of this article.

#### Funding

The author(s) received no financial support for the research, authorship, and/or publication of this article.

#### ORCID iD

Jaemin Ko, DDS, MS  <https://orcid.org/0000-0001-7174-2608>

#### References

- Ala-Mello S, Peippo M. The first Finnish patient with the Floating-Harbor syndrome: the follow-up of eight years. *Am J Med Genet A*. 2004;130A(3):317-319.
- Andersen E, Sonnesen L, Kjaer MS, Fischer Hansen B, Kjaer I. The prenatal cranial base complex and hand in Turner syndrome. *Eur J Orthod*. 2000;22(2):185-194.
- Capelozza Filho L, Normando AD, da Silva Filho OG. Isolated influences of lip and palate surgery on facial growth: comparison of operated and unoperated male adults with UCLP. *Cleft Palate Craniofac J*. 1996;33(1):51-56.
- De Benedetto MS, Mendes FM, Hirata S, Guare RO, Haddad AS, Ciamponi AL. Floating-Harbor syndrome: case report and craniofacial phenotype characterization. *Int J Paediatr Dent*. 2004;14(3):208-213.
- Enlow DH, Moyers RE. Growth and architecture of the face. *J Am Dent Assoc*. 1971;82(4):763-774.
- Eser M, Ayaz A, Yesil G. A case with Rubinstein-Taybi syndrome: a novel frameshift mutation in the CREBBP gene. *Turk J Pediatr*. 2017;59(5):601-603.
- Feingold M. Thirty-two year follow-up of the first patient reported with the Floating-Harbor syndrome. *Am J Med Genet A*. 2006;140(7):782-784.



- Pelletier G, Feingold M. Case report 1. *Syndrome Identification*. 1973; 1:8-9.
- Grayson BH, Weintraub N, Bookstein FL, McCarthy JG. A comparative cephalometric study of the cranial base in craniofacial anomalies: Part I: Tensor analysis. *Cleft Palate J*. 1985;22(2):75-87.
- Hood RL, Lines MA, Nikkel SM, Schwartzentruber J, Beaulieu C, Nowaczyk MJ, Allanson J, Kim CA, Wiczorek D, Moilanen JS, et al. Mutations in SRCAP, encoding SNF2-related CREBBP activator protein, cause Floating-Harbor syndrome. *Am J Hum Genet*. 2012;90(2):308-313.
- Houlston RS, Collins AL, Dennis NR, Temple IK. Further observations on the Floating-Harbor syndrome. *Clin Dysmorphol*. 1994; 3(2):143-149.
- Johnston H, Kneer J, Chackalaparampil I, Yaciuk P, Chrivia J. Identification of a novel SNF2/SWI2 protein family member, SRCAP, which interacts with CREB-binding protein. *J Biol Chem*. 1999; 274(23):16370-16376.
- Kehrer M, Beckmann A, Wyduba J, Finckh U, Dufke A, Gaiser U, Tzschach A. Floating-Harbor syndrome: SRCAP mutations are not restricted to exon 34. *Clin Genet*. 2014;85(5):498-499.
- Kreiborg S, Jensen BL, Bjork A, Skieller V. Abnormalities of the cranial base in cleidocranial dysostosis. *Am J Orthod*. 1981; 79(5):549-557.
- Lacombe D, Patton MA, Elleau C, Battin J. Floating-Harbor syndrome: description of a further patient, review of the literature, and suggestion of autosomal dominant inheritance. *Eur J Pediatr*. 1995;154(8):658-661.
- Le Goff C, Mahaut C, Bottani A, et al. Not all floating-harbor syndrome cases are due to mutations in exon 34 of SRCAP. *Hum Mutat*. 2013;34:88-92.
- Messina G, Atterato MT, Dimitri P. When chromatin organisation floats astray: the Srcap gene and Floating-Harbor syndrome. *J Med Genet*. 2016;53(12):793-797.
- Milani D, Scuvera G, Gatti M, Tolva G, Bonarrigo F, Esposito S, Gervasini C. Perthes disease: a new finding in Floating-Harbor syndrome. *Am J Med Genet A*. 2018;176(3):703-706.
- Monroy MA, Schott NM, Cox L, Chen JD, Ruh M, Chrivia JC. SNF2-related CBP activator protein (SRCAP) functions as a coactivator of steroid receptor-mediated transcription through synergistic interactions with CARM-1 and GRIP-1. *Mol Endocrinol*. 2003; 17(12):2519-2528.
- Nagasaki K, Asami T, Sato H, Ogawa Y, Kikuchi T, Saitoh A, Ogata T, Fukami M. Long-term follow-up study for a patient with Floating-Harbor syndrome due to a hotspot SRCAP mutation. *Am J Med Genet A*. 2014;164A(3):731-735.
- Nie X. Cranial base in craniofacial development: developmental features, influence on facial growth, anomaly, and molecular basis. *Acta Odontol Scand*. 2005;63(3):127-135.
- Nikkel SM, Dauber A, de Munnik S, Connolly M, Hood RL, Caluseriu O, Hurst J, Kini U, Nowaczyk MJ, Afenjar A, et al. The phenotype of Floating-Harbor syndrome: clinical characterization of 52 individuals with mutations in exon 34 of SRCAP. *Orphanet J Rare Dis*. 2013;8:63.
- Patton MA, Hurst J, Donnai D, McKeown CM, Cole T, Goodship J. Floating-Harbor syndrome. *J Med Genet*. 1991;28(3): 201-204.
- Quintanilla JS, Biedma BM, Rodriguez MQ, Mora MT, Cunqueiro MM, Pazos MA. Cephalometrics in children with Down's syndrome. *Pediatr Radiol*. 2002;32(9):635-643.
- Robinson PL, Shohat M, Winter RM, Conte WJ, Gordon-Nesbitt D, Feingold M, Laron Z, Rimoin DL. A unique association of short stature, dysmorphic features, and speech impairment (Floating-Harbor syndrome). *J Pediatr*. 1988;113(4):703-706.
- Saul RA, Wilson WG. A "new" skeletal dysplasia in two unrelated boys. *Am J Med Genet*. 1990;35(3):388-393.
- Seifert W, Meinecke P, Kruger G, Rossier E, Heinritz W, Wusthof A, Horn D. Expanded spectrum of exon 33 and 34 mutations in SRCAP and follow-up in patients with Floating-Harbor syndrome. *BMC Med Genet*. 2014;15:127.
- Singh A, Bhatia HP, Sood S, Sharma N, Mohan A. A novel finding of oligodontia and ankyloglossia in a 14-year-old with Floating-Harbor syndrome. *Spec Care Dentist*. 2017;37(6):318-321.
- Stagi S, Galluzzi F, Bindi G, Lapi E, Cecchi C, Salti R, Chiarelli F. Precocious puberty in a girl with floating-harbor syndrome. *J Pediatr Endocrinol Metab*. 2007;20(12):1333-1337.
- Tuysuz B, van Bon BW, Alp Z, Guzel Z, Veltman JA, de Vries BB. A microduplication of the Rubinstein-Taybi region on 16p13.3 in a girl with a bilateral complete cleft lip and palate and severe mental retardation. *Clin Dysmorphol*. 2012;21(4):204-207.
- Undiagnosed Diseases Network. Database on SRCAP. 2019. <https://undiagnosed.hms.harvard.edu/genes/srcap/>. Accessed January 14, 2019.
- White SM, Morgan A, Da Costa A, Lacombe D, Knight SJ, Houlston R, Whiteford ML, Newbury-Ecob RA, Hurst JA. The phenotype of Floating-Harbor syndrome in 10 patients. *Am J Med Genet A*. 2010;152A(4):821-829.
- Wiltshire E, Wickremesekera A, Dixon J. Floating-Harbor syndrome complicated by tethered cord: a new association and potential contribution from growth hormone therapy. *Am J Med Genet A*. 2005; 136(1):81-83.